# Parasites infecting GIT (practical 1)

By
Nahed Elossily
Professor of Medical Parasitology
Faculty of Medicine, Meri University

# Helminthes infecting GIT

# 1. Heterophyes heterophyes

| | |
|---|---|
| Habitat | ➢ between the villi of the small intestine. |
| Definitive host (D.H) | ➢ Man |
| Reservoir host | ➢ Cat, dog and any fish-eating animals. |
| Intermediate hosts (I.H) | ➢ 1st : Pirenella conica snails.<br>2nd is fish (Bolty and Boury). |
| Infective stage | ➢ Encysted metacercaria in the fish muscle. |
| Mode of infection: | ➢ By eating insufficient cooked, roasted or salted fish (sweet fesekh), containing the infective stage (encysted metacercariae). |

# *Heterophyes heterophes* adult worm

- Pear shaped with broad posterior end
- It has 3 suckers
  1. Ventral: large about the middle of the body
  2. Genital: surrounding the common genital pore
  3. Intestinal ceca: tow simple blind

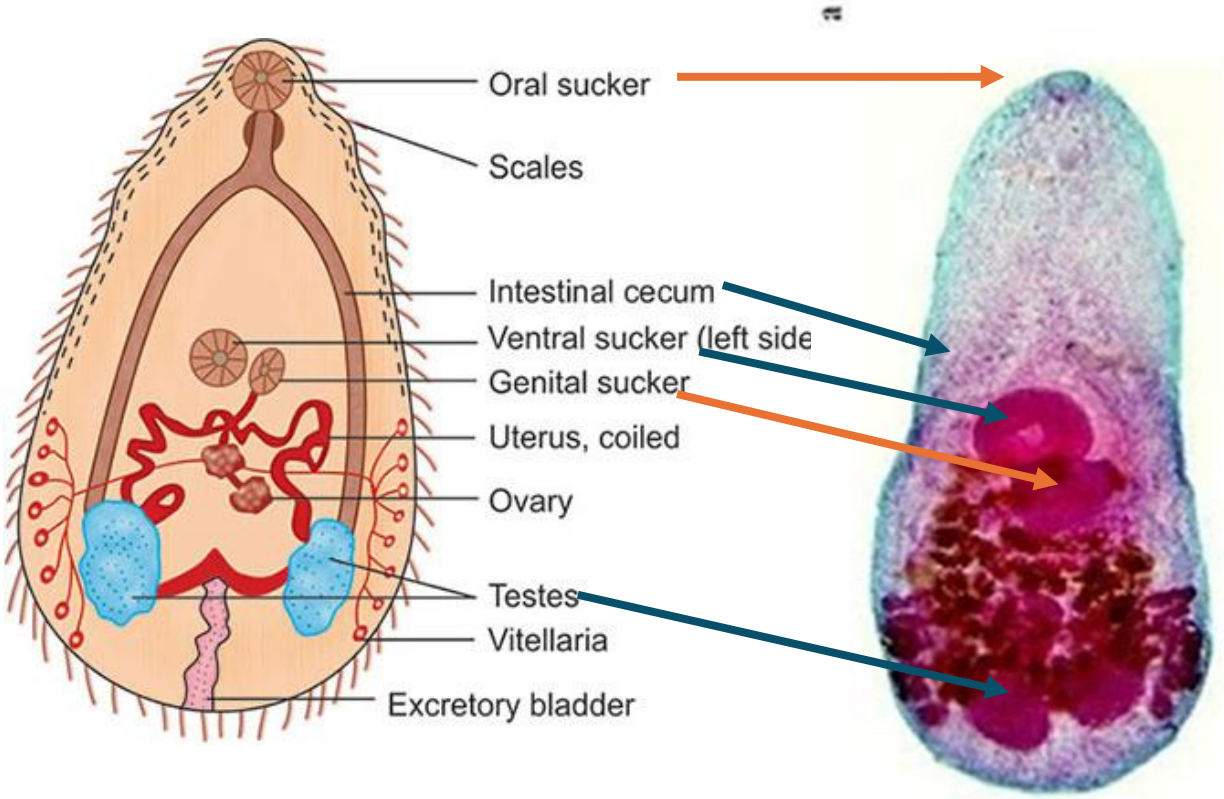


- Tests: 2 oval near the posterior end
- Ovary: rounded and small
- Uterus: coiled between intestinal caeca and filled with eggs

# *Heterophyes heterophes egg*

**Ova**: The egg is ovoid, operculate, elongate and light brown (almost yellow) in color. The egg contains the embryo (miracidium).
It measures 27 - 30µm by 15 – 17µm.

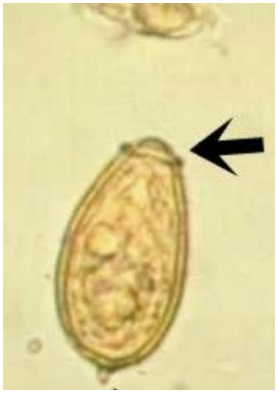

# *Heterophyes heterophyes*

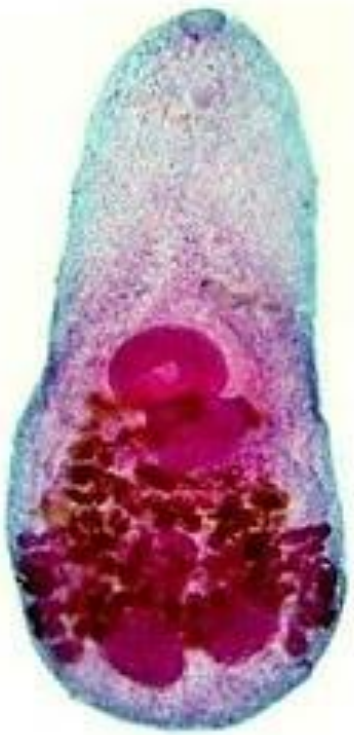

***Heterophyes heterophyes***
**Adult I**

**Egg: small, operculated, yellowish brown, thick shell**

# 2- *Hymenolepis nana* (Dwarf tape worm)

| | |
|---|---|
| **Geog. Dist.** | cosmopolitan. It is the commonest tape worm in children. |
| **Def. host (D.H)** | Man acts as definitive as well as intermediate host. |
| **Habitat** | Small intestine. |
| **Infective stage** | Eggs |
| **Mode of infection:** | 1. Ingestion of eggs with contaminated food or drink.<br>2. Autoinfection: it may be:<br>• External autoinfection, hand to mouth.<br>• Internal autoinfection could also occur when eggs hatch in the stomach leading to hyper-infection. |

# *Hymenolepis* nana egg

## Morphology *H. nana*

- Eggs generally measure between **30 to 47 microns** in diameter.
- They are round to oval, and should contain a six-hooked oncosphere.
- They have **polar filaments** that lie between the eggshell and the oncosphere.

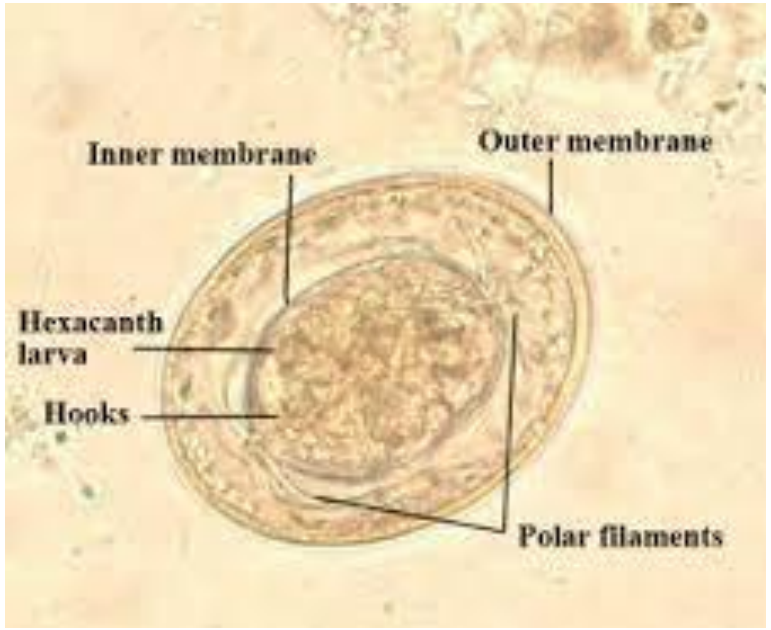

# 1. Taenia saginata (Beef tapeworm)

| The disease | Taeniasis saginata |
|---|---|
| Host | Found only in man (host specific). . |
| Intermediate host | Cattle. |
| Habitat | Small intestine. |
| Infective stage | Cysticercus bovis |
| Mode of infection | by ingestion of Cysticercus bovis in undercooked cattle meat |
| Diagnostic stage | Gravid segment which pass single with or without defecation as well as eggs in stool. |

# *Taenia saginata* scolex (beef tapeworm)

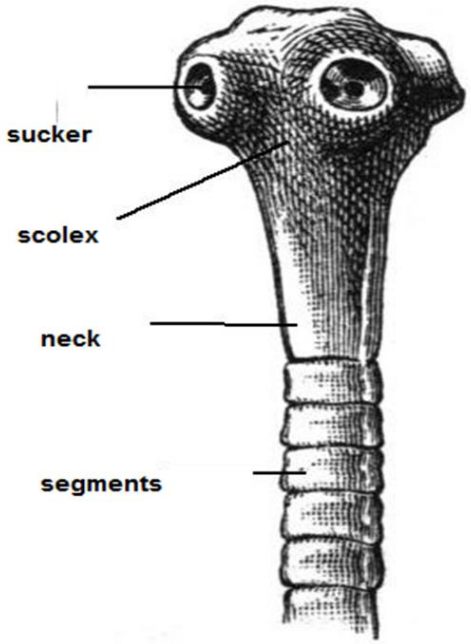


- **Host:** Man
- **Habitat:** Small intestine
- ***Taenia saginata* scolex :**

Globular in shape with 4 cup shaped suckers. No rostellum, no hooks.

# *Taenia saginata* gravid segment:

- Uterus consists of median longitudinal stem with 15-30 main uterine branches (on each side).

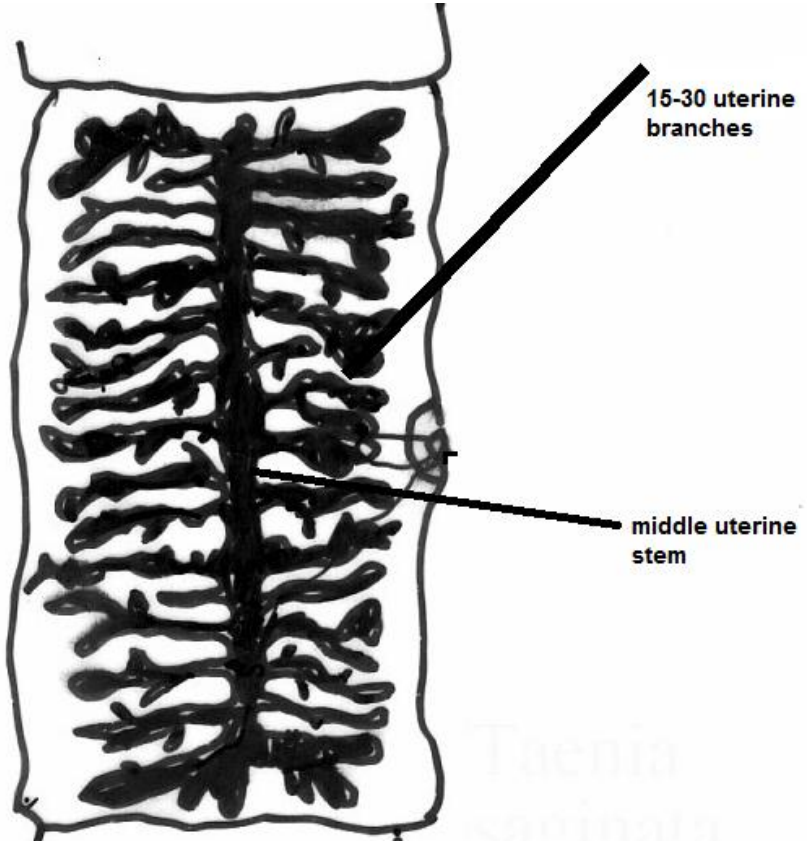

# 4- Taenia solium (Pork tapeworm)

| The disease | Taeniasis solium, Cysticercosis |
|---|---|
| Host | Found only in man (host specific). |
| Intermediate host | Pig and occasionally man (cysticercosis). |
| Habitat | Small intestine. |
| Infective stage | ➢ Cysticercus cellulosae ……. Taeniasis solium<br>➢ Egg……cysticercosis |
| Mode of infection | ➢ Adult worm: by ingestion of Cysticercus cellulosae in undercooked pork meat<br>➢ Cysticercosis by ingestion of egg by autoinfection or with contaminated food and water |
| Diagnostic stage | gravid segments which come out with stool in a chain of 2-3 segments as well as eggs |

# *Taenia solium* scolex

- With 4 cup-shaped suckers and rostellum. Rostellum armed with two crowns of hooks.

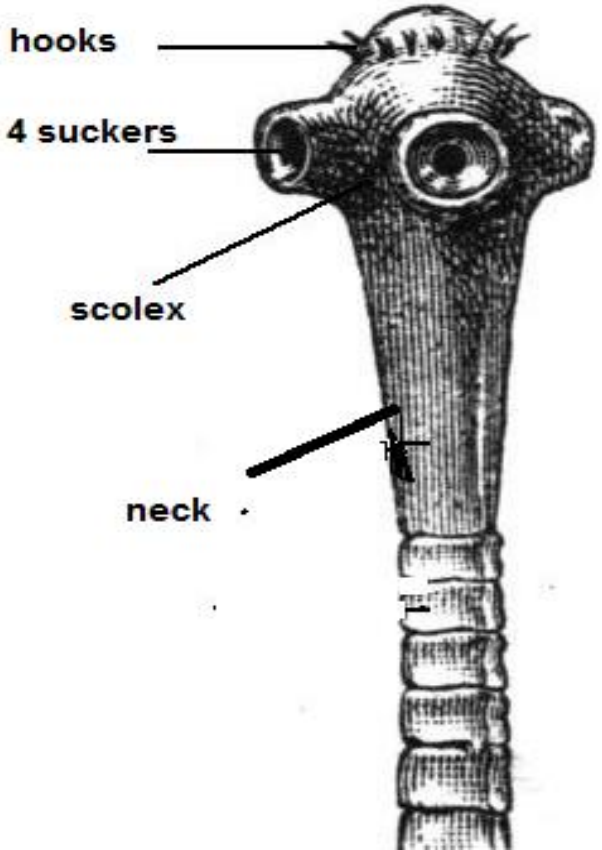

# *Taenia* spp. mature segment

- Slightly broader than longer.
- Contains bi-lobed ovary, the uterus is a simple tube in the median plane, testes are numerous and scattered throughout the segment .

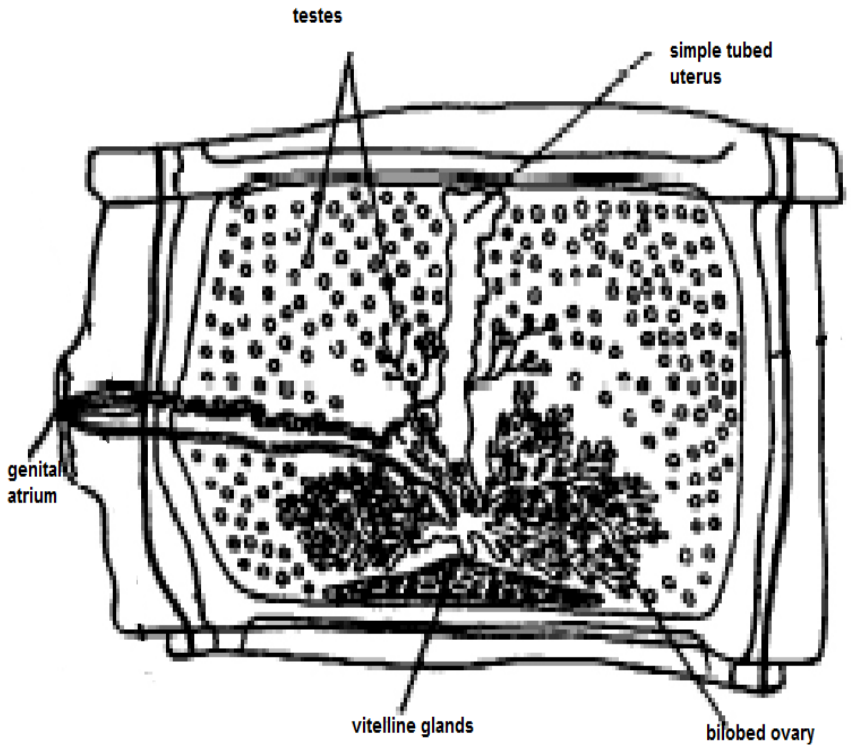


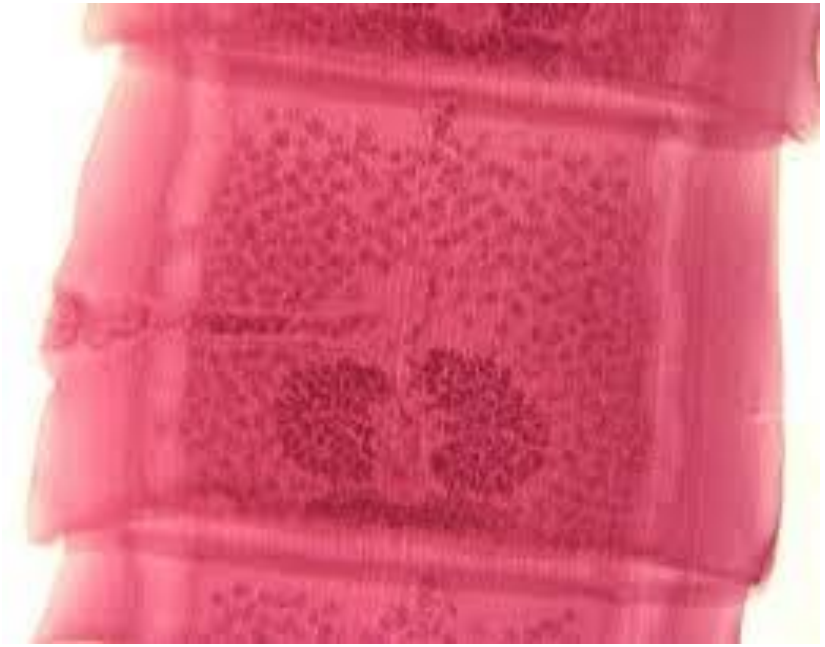

# *Taenia* spp. mature segment



# *Taenia solium* gravid segment:

Resembles that of *T. saginata* but differs in:

- Number of main uterine branches are 7 – 13 on each side of the uterine tube.
- Smaller in size.

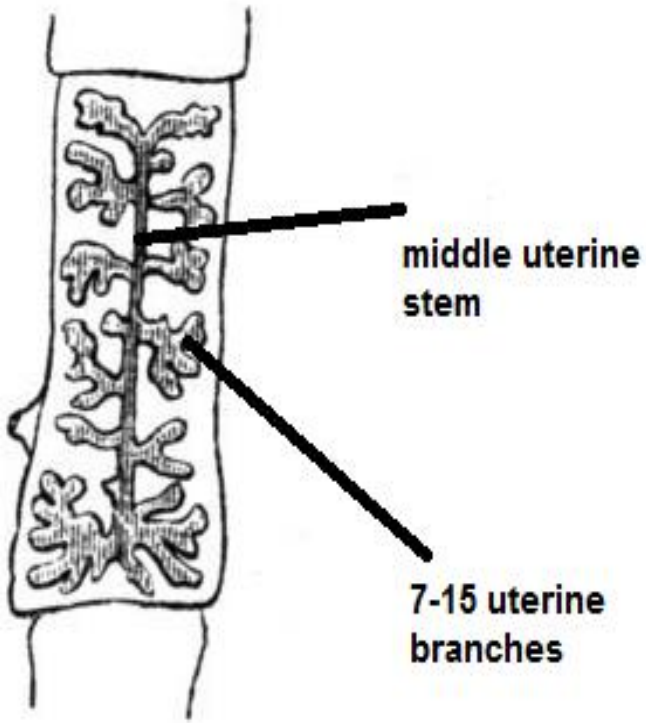



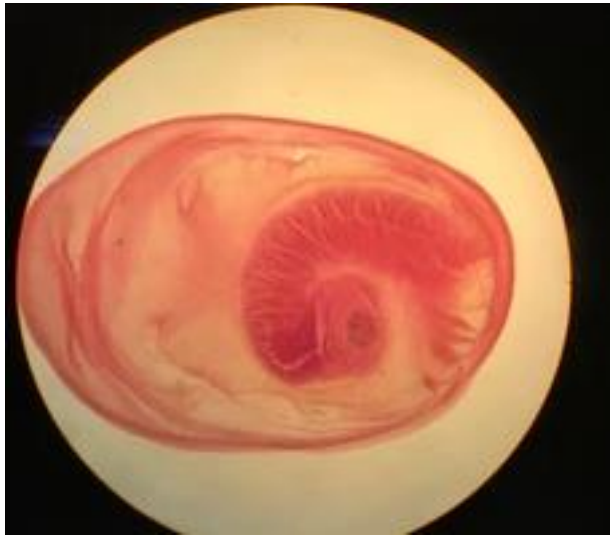

***Cysticercus celluosae* (larval stage of *Taenia solium*): :**
sit differs from Cysticercus bovis in the following

- The scolex has hooks (like adult ***T. solium***
- Developed in pig meat

# Egg

- The eggs of *Taenia saginata* and *T. solium* are indistinguishable morphologically.
- The eggs are spherical, diameter 31 to 43 µm, with a thick radially striated brown embryophore.
- Inside each is an oncosphere with 6 hooklets.

shutterstock.com · 2270899637

# 5- *Ascaris lumbricoides*

# (Giant intestinal roundworm)

| | |
|---|---|
| **Habitat** | Small intestine (free in the lumen). |
| **Definitive host** | Man |
| **Intermediate host** | It is specific parasite of man with no I.H.or R.H. |
| **Mode of infection** | Ingestion of embryonated eggs with contaminated water and food. Houseflies may carry the larvated eggs to human food. |
| **Infective stage** | Eggs containing second-stage rhabditiform larva. |
| **Diagnostic stage** | Fertilized or non fertilized egg in stool |

# Ascaris female are oviparous, produce 2 types of eggs

**1- fertilized eggs**

- Shape: round to oval
- Size: 60-75 x 50-60 µm
- Color: golden brown
- Content: unembryonated contain a round compact mass of granules
  Shell: thick composed of 3 layers; inner vitelline, middle transparent layer, outer irregular albuminoid layer.

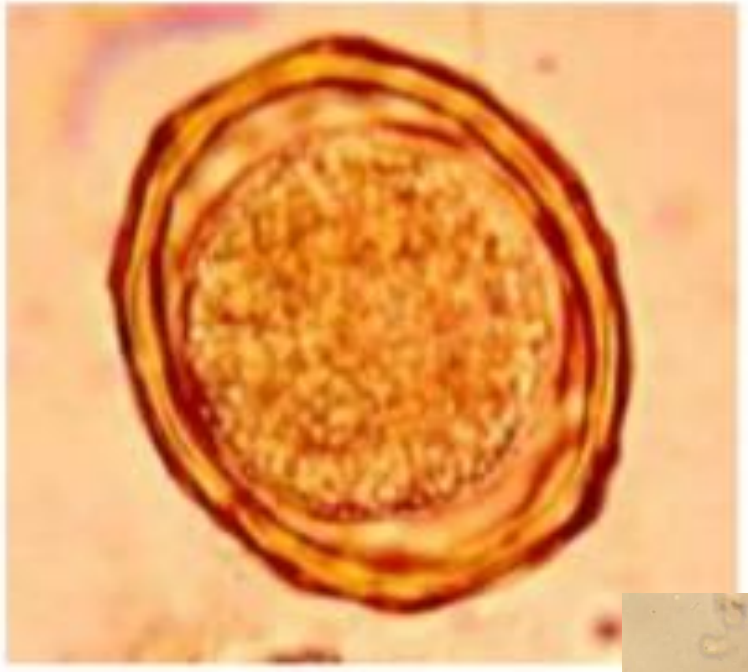

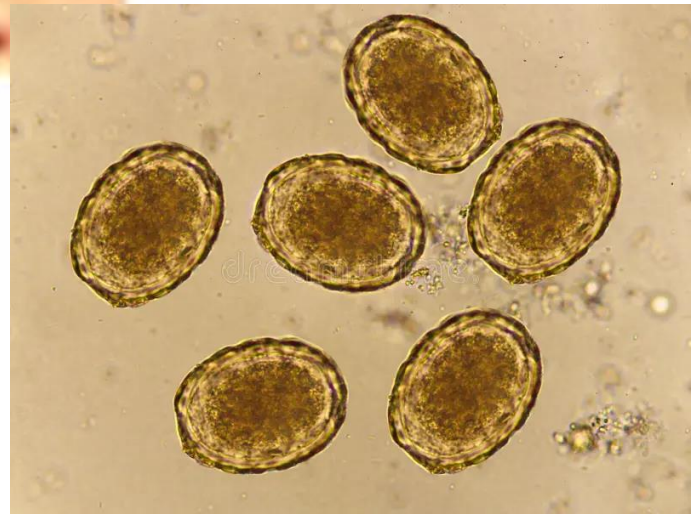

# 7-Ancylostoma duodenale

| | |
|---|---|
| **Habitat** | Small intestine |
| **Host** | Man |
| **Mode of infection** | Man is infected when the filariform larva (Infective stage) penetrates his intact skin or mucous membrane of the mouth. |
| **Infective stage** | 3rd stage larva (filariform larvae) |
| **Diagnostic stage** | Egg in stool |

# *Ancylostoma duodenale egg*

- **Shape** : oval with an empty space between the shell and content
- **Size**: 60 x 40 µm
- **Shell**: thin egg shell
- **Color**: colorless and transparent
- **Content**: 4-8 cell unembryonated
- Immature eggs pass in feces (20,000 eggs/day).



# 8. *Enterobius vermicularis*
# (Pin worm, Seat worm, Family worm)

| | |
|---|---|
| **Habitat:** | Large intestine mainly caecum, colon, rectum and appendix |
| **Final host** | Human specially children |
| **Infective stage** | embryonated eggs containing fully developed larvae. |
| **Mode of infection:** | ➢ **Ingestion** of eggs through contaminated food and drink or hand to mouth via handling contaminated articles as clothes, bed linens, toilet seats, doorknobs.<br>➢ **Autoinfection (external):** eggs are carried under fingernails to the mouth.<br>➢ **Internal autoinfection (Retro-infection):** eggs hatch on the perianal region and larvae migrates back through the anus to the rectum and caecum.<br>➢ **Air-borne infection**: inhalation of infective eggs |
| **Diagnostic stage:** | Fully embryonated eggs containing fully developed larvae. |
| **Diagnostic method** | Scotch tape or NIH Swab (National Institute of Health) |

# Enterobius vermicularis

## Morphology (the worm)

**Shape**: round

**Color**: white

**Size:**

**Females**: 8 to 13 mm long

**males:** 2 to 5mm long

**posterior end:**

Tapered in females

curved in males

**anterior part(cervical alae):**

found in both male and female worms

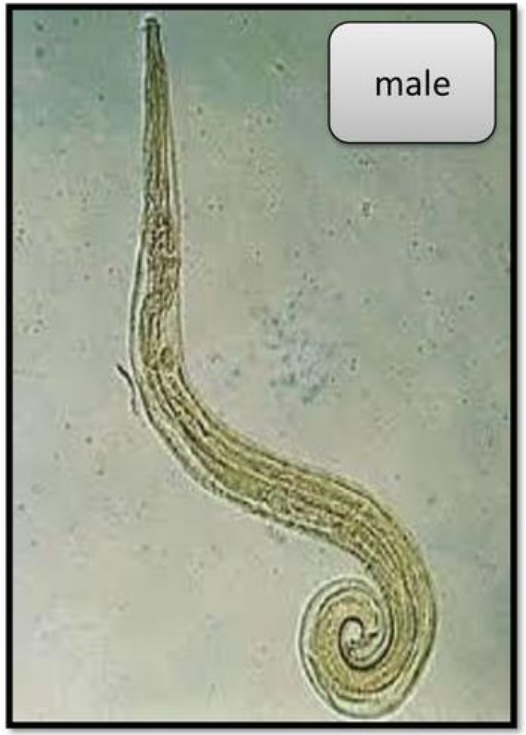

# Eggs of E. vermicularis

**E.vermicularis are oviparous worms**

**Shape**: D shaped

**Size**:50- 60 x 20-30 µm

**Color**: colorless

**Shell**: thin

**Contents:**

- Single cell ( immature egg) or
- Larva (mature egg)

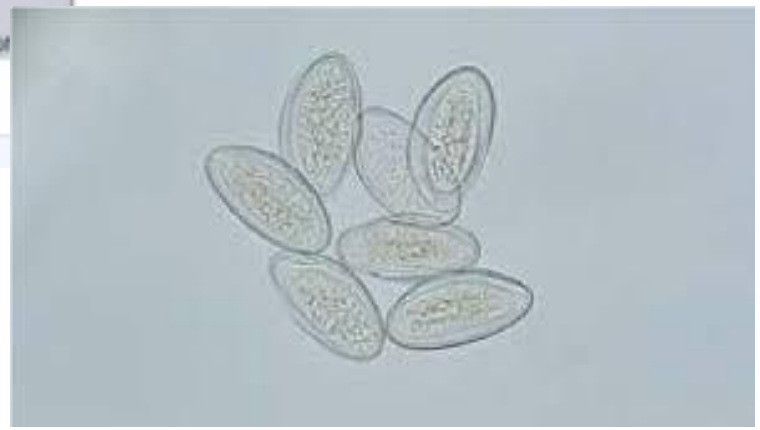

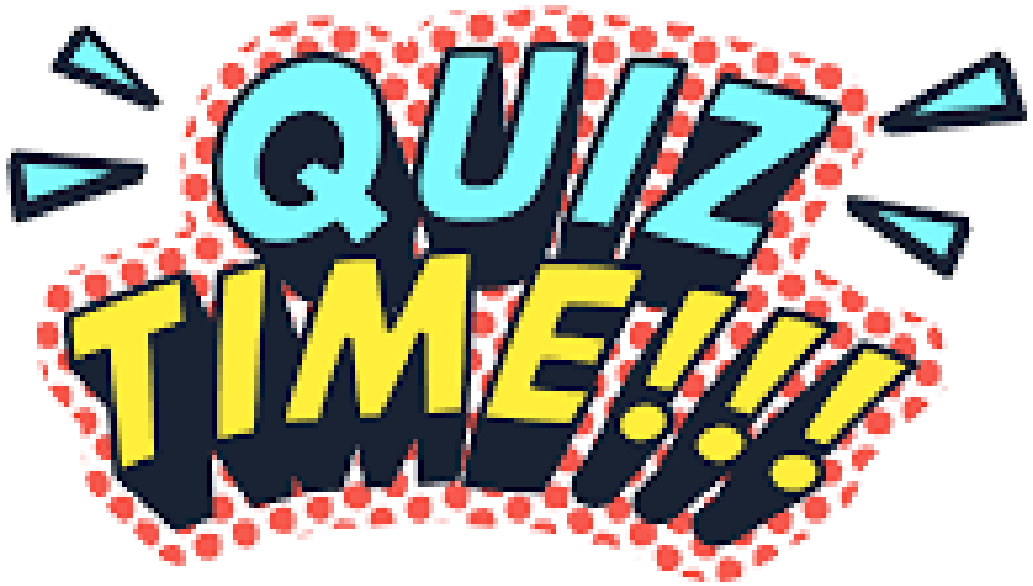
QUIZ
TIME!!!!

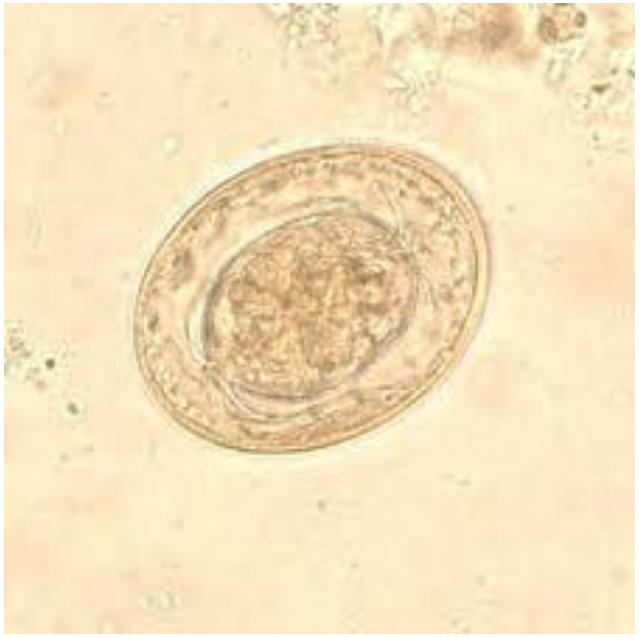

1. **Identify the parasite (mention genus, species and stage)**
2. **Mention diagnostic stage**
3. **Mention infective stage**
4. **Mode of infection**
5. **Mention the habitat**
6. **Mention the definitive host**

A

B

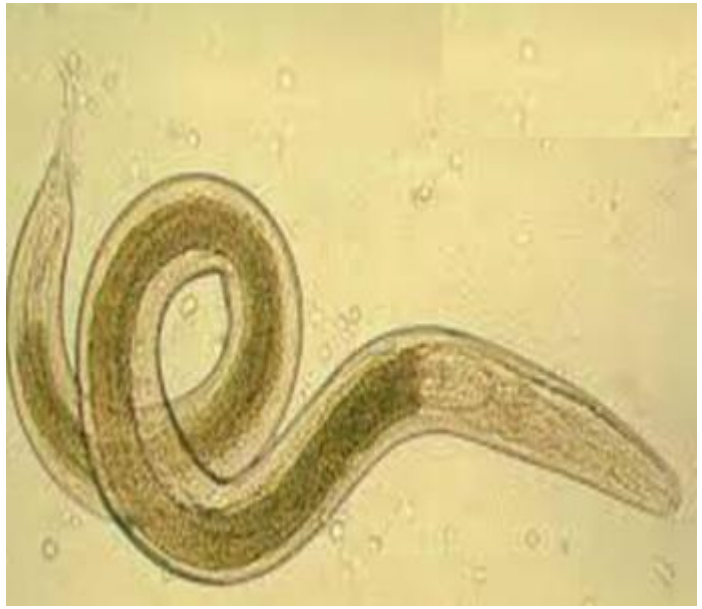

C

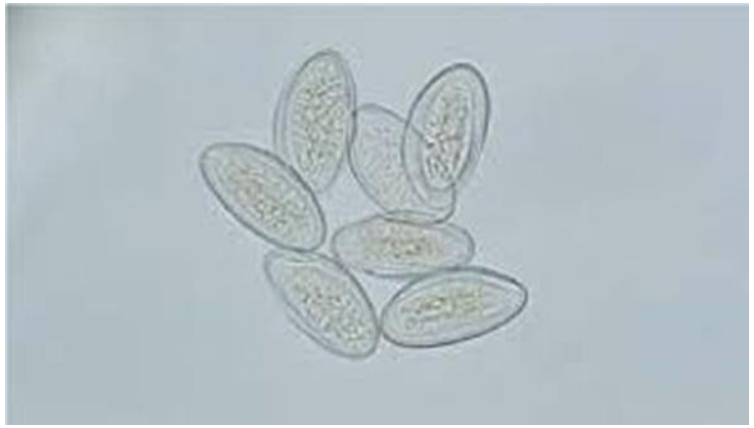

1. Identify the parasite (mention genus, species and stage)
2. Mention diagnostic stage
3. Mention infective stage
4. Mode of infection
5. Mention the habitat
6. Mention the definitive host

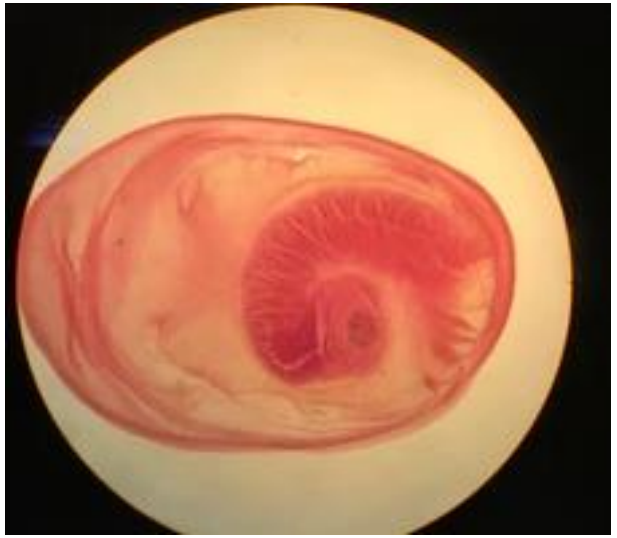

1. **Identify the parasite (mention genus, species and stage)**
2. **Mention diagnostic stage**
3. **Mention infective stage**
4. **Mode of infection**
5. **Mention the habitat**
6. **Mention the definitive host**
7. **Mention the intermediate host**

1. **Identify the parasite (mention genus, species and stage)**
2. **Mention diagnostic stage**
3. **Mention infective stage**
4. **Mode of infection**
5. **Mention the habitat**
6. **Mention the definitive host**
7. **Mention the intermediate host**

1. **Identify the parasite (mention genus, species and stage)**
2. **Mention diagnostic stage**
3. **Mention infective stage**
4. **Mode of infection**
5. **Mention the habitat**
6. **Mention the definitive host**

A

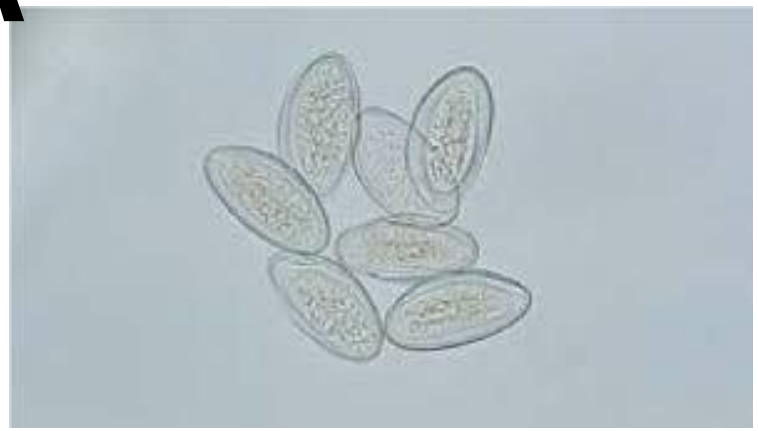

B

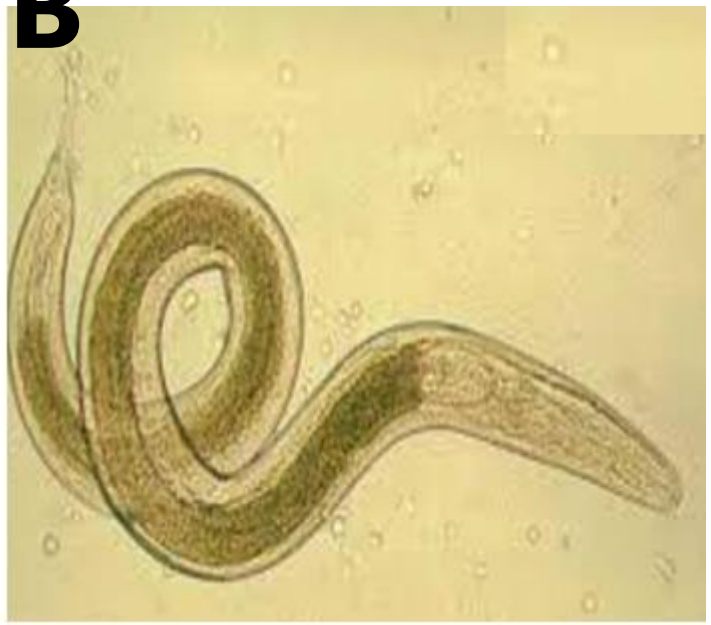

C

1. Identify the parasite (mention genus, species and stage)
2. Mention diagnostic stage
3. Mention infective stage
4. Mode of infection
5. Mention the habitat
6. Mention the definitive host
7. Mention the intermediate host